The veterinary nurse's clinical journal for veterinary nurses
Number 1 Volume 10 February 2019
SEARCH TVN



# The role of the RVN in treating dystocia in mares

Maria Rippingale
Wednesday, July 2, 2014

Delivering high quality and appropriate care to patients is central to the role of registered veterinary nurses (RVNs) and this includes those undergoing dystocia treatment. Providing anesthetic care to these patients is an extremely high standard is required. Horses are different to small animals as they are only designed to carry and produce one offspring at a time. For this reason equine specific knowledge is required to ensure the best care is provided to the mare and foal. This article will discuss the role of the RVN in equine dystocia, equine specific knowledge is required for veterinary registered veterinary nurses (RVNs) assisting with dystocia and the use of equipment and pharmacology will be discussed as well as the general preparation for equine nursing interventions.

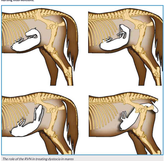

Peer reviewed and evidence based
SUBMIT YOUR ARTICLE
Twitter
Connect with us on Twitter
Stay ahead of the latest developments in practice
FOLLOW US
Facebook
Connect with us on Facebook
Add the latest clinical best practice to your newsfeed
FOLLOW US



The role of the RVN in treating dystocia in mares

The incidence of dystocia in mares is approximately 1-3% (Frazer,2008). Prolonged dystocia is as high as 10% in some breeds (Frazer,2008). Dystocia is a medical emergency and requires immediate veterinary intervention and equine practice where veterinary nurses make a difference to the survival of the foal (Embertson, 2012). Dystocia in dystocia also influences the degree of reproductive tract trauma that occurs during resolution of the dystocia. Equine specific knowledge is required for veterinary registered veterinary nurses (RVNs) assisting with dystocia and equine specific knowledge is required for veterinary registered veterinary nurses (RVNs) assisting with dystocia and the use of equipment and pharmacology will be discussed as well as the general preparation for equine dystocia in the mare. Recurring interventions for uterine torsion, fetal malpresentation and retained fetal membranes (RFM) will be discussed.

## Parturition

Parturition is the term used to describe the expulsion of the fetus and the fetal membranes from the uterus through the maternal passages by natural forces (Purcell, 2012). Parturition is divided into three stages: Isovolus and the conditions chosen for discussion occur at different stages of the parturition process.

### First stage labour

This first stage of labour lasts for 1 to 4 hours with the onset of uterine contractions. Signs include lying down, sweating, tail swishing, pacing, and colic. Uterine contractions are initiated by oxytocin secreted from the posterior Fetal membranes and the mare's udder and genitalia are all down lying the fetal membranes from a dorsoventral dorsoventral to a dorsal position with the pub. neck and hindlimbs flexed (Brinsfield et al, 2012). As this stage progresses the fetal membrane (FM) and the fetal membrane (FM) and the fetal membrane (FM) are both in the uterus and cervix. See Figure 1.

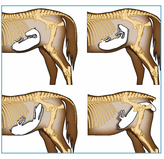

Figure 1. Relation of the foal at stage 1 labour. The foal remains in dorsoventral or dorsal-ventral position until stage one labour commences (Lopate et al, 2003).

### Uterine torsion

Torsion of the uterus constitutes 5 -10% of all serious equine dystocias, with 10% of uterine torsions occurring during parturition in the first stage of labour (Vandeplassche et al, 1993). The pathophysiology of uterine torsion is complex and is beyond the scope of this article. The pathophysiology of uterine torsion and cervix has been discussed as a contributing factor in the process (Laffers, 1999).

### Nursing care for uterine torsions

Frazer et al (2002) stated that to correct a uterine torsion, a well lubricated arm may be passed into the uterine body, where it may be possible to grasp the fetus extremidades. The fetus and uterus can then be rocked back and forth to correct the torsion. Fetal membranes may be ruptured and the fetus delivered if necessary. Removal of the placenta would be an important part of the role of the RVN during this procedure. Frazer et al (2002) recommended using a crotch as a useful way to quickly initiate a mare for rectal/vaginal examination and to hold the tail. Frazer et al (2002) also recommended using a crotch for uterine torsion. Frazer et al (2002) Vandeplassche and Frontoniani (2012) however, stated that a crotch carries the risk of causing pain and discomfort to the mare and should be used with caution. Vandeplassche and Frontoniani (2012) stated that on occasion a horse may react unexpectedly when a crotch is used and this is where the equine handling skills of the veterinary nurse are important. The veterinary nurse should be able to recognise the signs of pain and distress the crotch can present potential stress to the patient and injury to the crotch by assisting veterinary surgeon (VS).

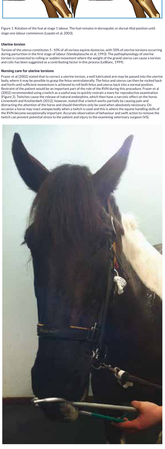

Figure 2. Human testicles are often used to restrain horses for different veterinary procedures.

Frazer et al (2002) also advocated the use of standing flank laparotomy to correct uterine torsions. In the standing flank approach, a grid incision is made on the same side as the direction of the torsion. The torsion is corrected by placing the forearm under the uterus and gently rocking back and forth to gain momentum and correct the torsion (Frazer et al, 2002). Frazer et al (2002) stated that the fetal membranes (FM) and the author's practice also suggested that the uterus should normally be clipped for the sake of surgery should a rupture occur. Frazer et al (2002) stated that the uterus should be clipped in the case of a rupture